



Left posterior BA37 is involved in object recognition: a TMS study

Lauren Stewart ^{a,*}, Bernd-Ulrich Meyer ^{b,c}, Uta Frith ^a, John Rothwell ^b

^a *Institute of Cognitive Neuroscience, University College London, Alexander House, 17 Queen Square, London WC1N 3AR, UK*

^b *MRC Human Movement and Balance Unit, Institute of Neurology and National Hospital for Neurology and Neurosurgery, Queen Square, London WC1N 3BG, UK*

^c *Department of Neurology, Charite' Humboldt-University, Berlin, Germany*

Received 15 March 2000; received in revised form 14 June 2000; accepted 12 July 2000

Abstract

Functional imaging studies have proposed a role for left BA37 in phonological retrieval, semantic processing, face processing and object recognition. The present study targeted the posterior aspect of BA37 to see whether a deficit, specific to one of the above types of processing could be induced. Four conditions were investigated: word and nonword reading, colour naming and picture naming. Repetitive transcranial magnetic stimulation (rTMS) was delivered over posterior BA37 of the left and right hemispheres (*l*BA37 and *r*BA37, respectively) and over the vertex. Subjects were significantly slower to name pictures when TMS was given over *l*BA37 compared to vertex or *r*BA37. rTMS over *l*BA37 had no significant effect on word reading, nonword reading or colour naming. The picture naming deficit is suggested to result from a disruption to object recognition processes. This study corroborates the finding from a recent imaging study, that the most posterior part of left hemispheric BA37 has a necessary role in object recognition. © 2000 Elsevier Science Ltd. All rights reserved.

Keywords: Picture naming; Word reading; Nonword reading

1. Introduction

Several functional roles have been attributed to an area of posterior inferior temporal cortex, commonly referred to as BA37. These include general language processing [17,18], semantic processing [7–9,19,20,34], phonological retrieval [4,25,36], face processing [6,10,14,15,26] and object recognition [22,24,27,28,37]. A recent functional imaging study [21] claims that this area can be subdivided into three distinct subregions. The most posterior part is claimed to be involved in object recognition processes, an adjacent site 2 cm anterior is thought to be important for phonological retrieval whilst semantic processing is suggested to occur in the most anterior part of BA37.

The use of functional imaging to illustrate an area's functional specificity relies on the demonstration of a

correlation between regional cerebral blood flow and performance of a task requiring a particular type of processing. Such studies, by themselves, do not prove that the area of activation observed is necessary for the particular task under observation; such an assertion can only be made by lesion studies [13]. Transcranial magnetic stimulation produces a transient and reversible 'virtual lesion' [2,35] in normal subjects and as such can build on hypotheses derived from functional imaging to demonstrate that a given area is necessary for a particular type of processing. The aim of the present study was therefore to use TMS to probe the functional specificity of left hemispheric BA37. Guided by recent imaging studies, the most posterior part of BA37 was targeted, which is suggested to be involved in object processing [21]. If TMS could produce a deficit specific to object recognition but not to semantic or phonological processing, it will have been established that activity within this area of cortex is not only correlated with but necessary for object recognition.

* Corresponding author. Tel.: +44-171-3911168; fax: +44-171-8132835.

E-mail address: l.stewart@ucl.ac.uk (L. Stewart).

2. Methods

2.1. Subjects

Subjects were given an information leaflet explaining the procedures to be used and were given at least 24 h to decide whether they wished to participate. Subjects signed a consent form and reported absence of epilepsy or any other form of neurological condition in themselves and their family. They were also screened for the presence of metallic implants. Local ethical committee approval was granted for all procedures.

Eight subjects, six males and two females, aged between 25 and 55, two of which had taken part in previous TMS experiments, participated. All were right handed and had normal or corrected to normal vision. All were naive to the purpose of the experiment.

2.2. Stimuli

All stimuli were generated using Superlab software run on a Macintosh PowerBook 1400c laptop with a screen subtending $21.4 \times 16.3^\circ$ of visual angle. All stimuli were presented in the centre of the screen.

2.3. Words

A total of 180 word stimuli were used. These were the word forms of the stimuli used in the picture condition below. On average, stimuli subtended $0.6 \times 2.3^\circ$ of visual angle and were written in Arial font.

2.4. Nonwords

A total of 180 nonword stimuli were used. These were constructed to be pronounceable and to encompass a range of difficulties, indexed by naming latency. On the basis of results from a pilot study, the nonwords chosen had a mean latency similar to that for the picture stimuli. As above, stimuli subtended an average of $0.6 \times 2.3^\circ$ of visual angle and were written in Arial font.

2.5. Colours

Patches which were either blue, black, red, green, white, pink or grey were used. These patches were $1.9 \times 1.9^\circ$ of visual angle in size flanked each side by a patch of a different colour.

2.6. Pictures

A total of 180 picture stimuli (picture forms of the above word stimuli) were used. These mostly comprised Snodgrass and Vanderwaart [29] line drawings; the remainder were line drawings of other everyday objects.

Stimulus size was, on average, $6.7 \times 6.7^\circ$ of visual angle.

2.7. TMS

The stimulator used was a Magstim TM model 200 with two external boosters. The stimulating coil was of a figure-of-eight configuration, each winding measuring 70 mm (maximum output 2T). The double coil windings carry two currents in opposite directions such that, where the two loops meet, there is a localised summation of current and stimulation is more focal than with coils with a single winding [33]. Previous studies have demonstrated that stimulation using this type of coil can produce functionally dissociable effects that are restricted to an area with a radius of 0.5–1 cm on the scalp [3]. The centre of the coil was positioned over the site to be stimulated such that the windings extended at an angle of 90° to the spine.

2.8. Selection of TMS site

TMS was applied to a region corresponding to posterior BA37 of the left hemisphere (*l*BA37) and a site 3 cm behind the vertex (*Vx*). In the majority of subjects, posterior BA37 of the right hemisphere (*r*BA37) was also stimulated. The vertex stimulation site served as a control site so that the general facilitatory effects of TMS [32] could be controlled for. The right posterior BA37 served as a different kind of control; one which would enable any lateralised effects to be demonstrated. The locations of these sites were determined on the basis of an anatomical MRI scan from subject 1, aided by reference to an anatomical brain atlas [31]. Scalp landmarks were indicated by gelatine capsules which showed up as dense white blobs on the scans. Fig. 1 shows the MRI of subject 1; the white bar represents the position and orientation of the stimulation coil and the arrow shows that the closest point of contact between the coil and the cortex was the posterior aspect of BA37. Stimulation sites in the other subjects were over the same scalp location as in subject 1 but with some adjustments made to take into account individual differences in skull size and shape. BA37 sites ranged between 0 and 2.5 cm dorsal and 4–7 cm lateral with respect to theinion.

2.9. Procedure

Each stimulus set (words, nonwords, colours, pictures) was presented in a different session. In each case, the stimuli were presented in 15 blocks of 12. Stimuli were blocked on the basis of a pilot study in which reading/naming latency for each stimulus was recorded in six subjects. This enabled the stimuli to be distributed in such a way that the average response latency

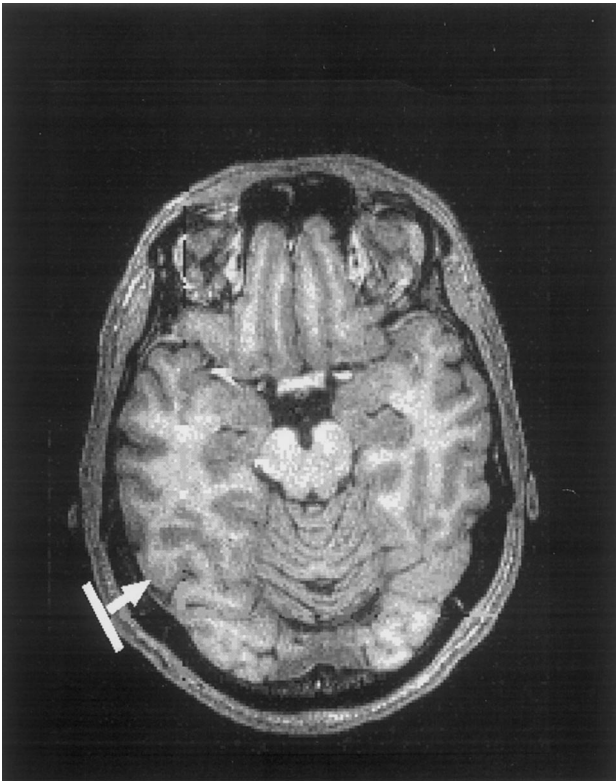

Fig. 1. Structural MRI of subject JR. An axial slice is shown. The white bar represents the position and orientation of the stimulating coil; the arrow indicates that the closest point of contact between the coil and the cortex was the posterior aspect of BA37.

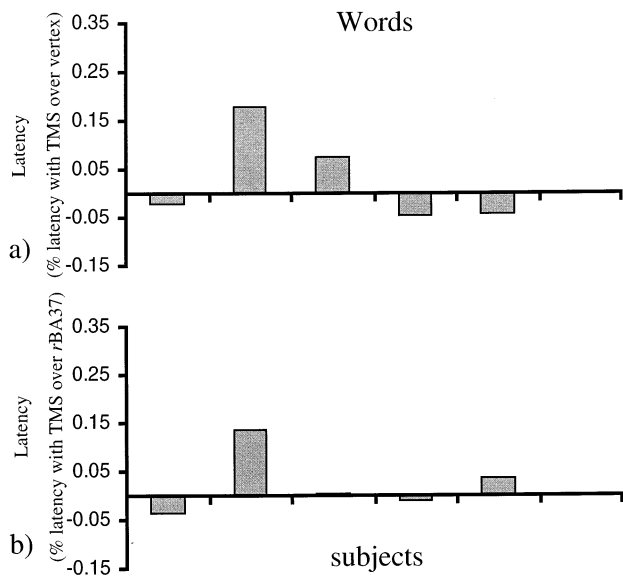


Fig. 2. (a) Average word reading latency in five subjects when stimulation was applied over left posterior BA37 (*lBA37*), expressed as a percentage of latency when stimulation was applied over the vertex (*Vx*). (b) Average word reading latency in five subjects when stimulation was applied over left posterior BA37 (*lBA37*), expressed as a percentage of latency when stimulation was applied over the right posterior BA37 (*rBA37*).

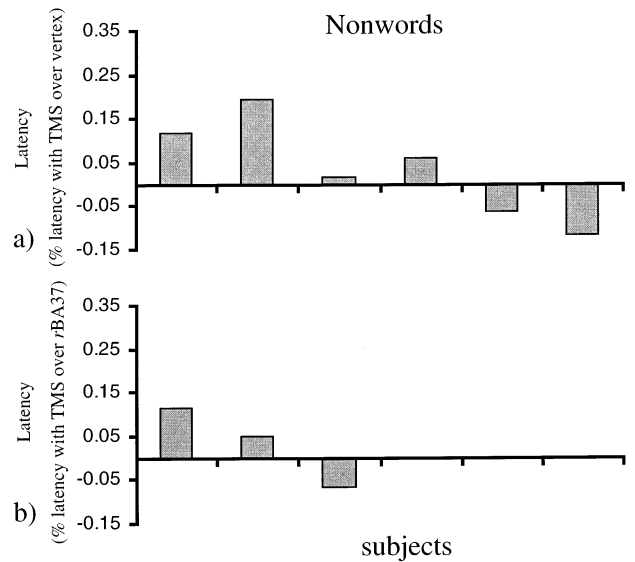


Fig. 3. (a) Average nonword reading latency in six subjects when stimulation was applied over *lBA37*, expressed as a percentage of latency when stimulation was applied over the *Vx*. (b) Average nonword reading latency in three subjects when stimulation was applied over *lBA37*, expressed as a percentage of latency when stimulation was applied over the *rBA37*.

and the range of response latencies was matched between blocks. Blocks were separated by 5 s during which the screen would be blank. An auditory tone of 500 ms preceded stimulus presentation, and stimuli appeared on the screen for a total of 3000 ms. TMS was applied at 75% (1.5 T) at a rate of 10 Hz for 600 ms in each subject. A recent study which has been conducted [30] indicates that a subject's motor threshold does not correlate with the same subject's phosphene threshold. From this finding it can be concluded that motor threshold is not a suitable guide by which to standardise stimulation intensity across subjects when stimulation is applied to non-motor areas. For this reason the present study used the same intensity of stimulation for each subject. The coil was placed over each of the three sites in turn, changing site at the end of each block and the order of stimulation sites was randomised between subjects. Subjects were required to read the word/nonword or name the colour/picture as quickly as possible. The subject's voice was recorded by microphone and sampled by computer for a 3 s period at the start of each trial. Voice onset for each trial was measured offline and manually at the end of the experiment. The median voice onset time for each condition (words, nonwords, colours, pictures) was calculated for each site of TMS delivery (*lBA37*, vertex, *rBA37*).

3. Results

Naming latencies are given as a percentage of the latency when stimulation was applied over Vx (Figs. 1a,

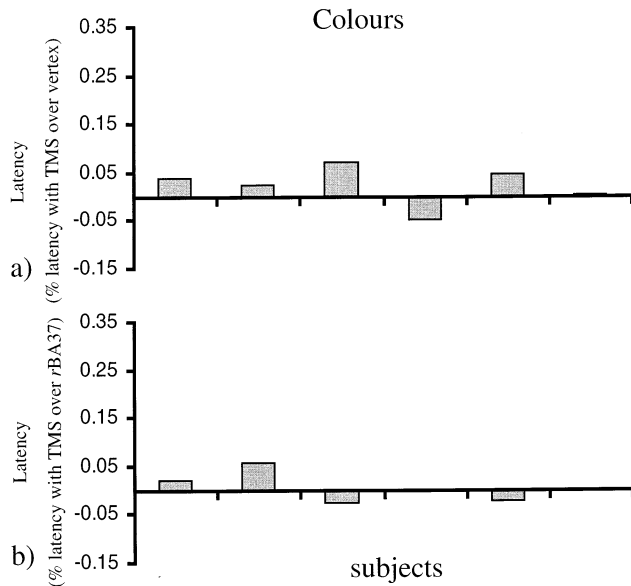


Fig. 4. (a) Average colour naming latency in six subjects when stimulation was applied over IBA37, expressed as a percentage of latency when stimulation was applied over the Vx. (b) Average nonword reading latency in five subjects when stimulation was applied over IBA37, expressed as a percentage of latency when stimulation was applied over the rBA37.

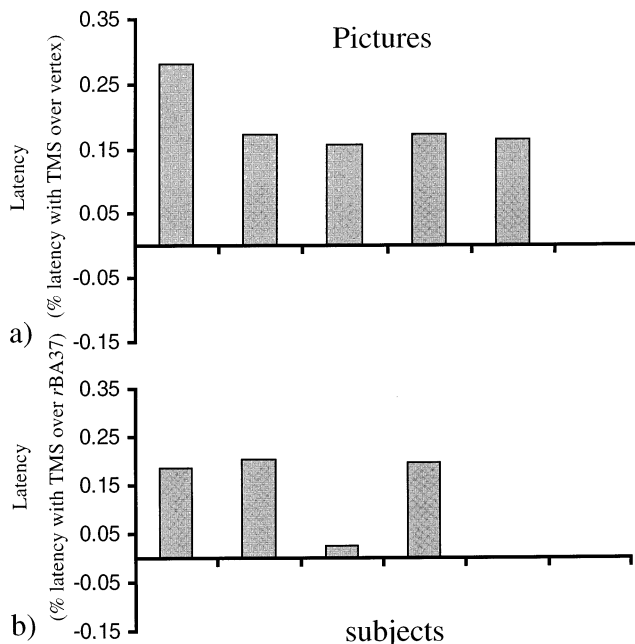


Fig. 5. (a) Average picture naming latency in five subjects when stimulation was applied over IBA37, expressed as a percentage of latency when stimulation was applied over the Vx. (b) Average picture naming latency in four subjects when stimulation was applied over IBA37, expressed as a percentage of latency when stimulation was applied over the rBA37.

2a, 3a and 4a) or over rBA37 (Figs. 1b, 2b, 3b and 4b). Since each condition (words, nonwords, colours and pictures) used a similar, though not identical, combination of subjects, the data from individual subjects is presented. *T*-tests were used for the analysis.

3.1. Word reading

Results for word naming are shown in Fig. 2a and b. Actual median latencies when stimulation was applied over Vx were 458, 349, 466, 419 and 463 ms. Subjects 1, 3, 4 and 5 showed no significant difference in latency to read words when stimulation was given over IBA37 compared to the Vx site or compared to rBA37 ($P > 0.05$ in all cases, Fig. 2a and b). Subject 2, however, showed a significant increase in latency to read words when stimulation was given over IBA37 compared to both the Vx site and rBA37 ($P < 0.01$ in both cases, Fig. 2a and b).

3.2. Nonword reading

Results for nonword reading are shown in Fig. 3a and b. Actual median latencies when stimulation was applied over Vx were 783, 588, 730, 827, 849 and 800 ms. None of the subjects showed an increase in latency to read nonwords when stimulation was given over IBA37 compared to the Vx site ($P \geq 0.05$ in all cases, Fig. 3a). Subjects 4, 5 and 6 also received TMS over rBA37 and latency to read nonwords was no different when stimulation was applied at this site compared with stimulation over Vx or rBA37 ($P \geq 0.05$ in all cases, Fig. 3a and b).

3.3. Colour naming

Results for colour naming are shown in Fig. 4a and b. Actual median latencies when stimulation was applied over Vx were 651, 602, 779, 485, 636 and 680 ms. None of the subjects showed an increase in latency to name pictures when stimulation was given over IBA37 compared to the Vx site ($P \geq 0.05$ in all cases, Fig. 4a). Subjects 1, 2, 4, 5 and 6 also received TMS over rBA37 and latency to name pictures was no different when stimulation applied at this site was compared with stimulation over Vx or rBA37. ($P \geq 0.05$ in all cases, Fig. 4a and b).

3.4. Picture naming

Results for picture naming are shown in Fig. 5a and b. Actual median latencies when stimulation was ap-

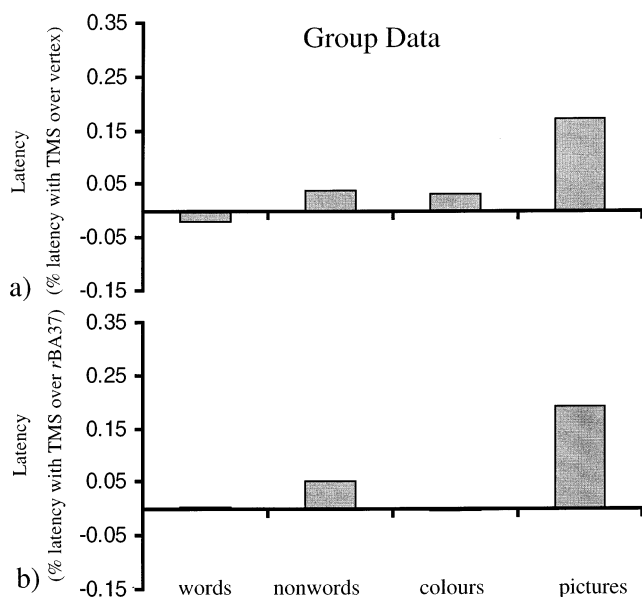


Fig. 6. (a) Latencies are averaged across subjects for each condition. Latencies are expressed as a percentage of latency when stimulation was applied over the Vx. (b) Latencies are averaged across subjects for each condition. Latencies are expressed as a percentage of latency when stimulation was applied over *rBA37*.

plied over Vx were 631, 717, 702, 786 and 701 ms for subjects 1–5, respectively. All five subjects tested showed a significant increase in latency to name the pictures when stimulation was given over *lBA37* compared with the Vx site (Subjects 1, 2 and 4: $P \leq 0.01$; subjects 3 and 5: $P \leq 0.05$, Fig. 5a). The average delay produced by TMS over *lBA37* across all five subjects was 119 ms. Subjects 1–4 who also received TMS over *rBA37* showed no significant difference in latency to name pictures when stimulation was given over this site compared to the Vx site ($P > 0.05$ in all cases, Fig. 6a). In subjects 1, 2 and 4 stimulation applied over *lBA37* site also produced significantly longer naming latencies compared with stimulation given over *rBA37* (subjects 1 and 2: $P \leq 0.01$; subjects 3 and 4: $P \leq 0.05$, Fig. 6b).

4. Discussion

This study has shown that rTMS applied over posterior BA37 of the left hemisphere greatly disrupts picture naming but leaves word reading, nonword reading and colour naming unaffected. The finding that there was no significant delay in naming when TMS was applied over the vertex or the analogous right hemispheric site precludes an explanation in terms of a non-specific effect of TMS.

Reading of words was unaffected, suggesting that TMS was not affecting phonological processing. This is confirmed by the finding that nonword reading, which requires greater phonological processing, was also unaf-

ected. The possibility that the picture naming deficit was due to interference with semantic processing is also unlikely since word reading also involves access to the semantic lexicon [23] yet was unaffected. This fits with the recent imaging results [21] which suggest that the semantic subregion of BA37 is positioned approximately 4 cm anterior to where the coil was positioned in this study. Finally, the fact that colour naming was unaffected argues against disruption to low level visual perceptual processes.

It was concluded that the picture naming deficit was most likely due to an effect of TMS on object recognition processes. This is in good agreement with neuropsychological reports that lesions to this area result in object recognition deficits [1,2,5,11,12] and with functional imaging results in which activity in posterior BA37 of the left hemisphere is seen during object recognition tasks [16,21,22,24,27,28,37]. TMS complements both the neuropsychological and neuroimaging evidence for this area's involvement in object recognition. Firstly, unlike neuropsychological cases where lesions tend to be quite diffuse and often not restricted to a single area, TMS can provide a 'virtual lesion' which is focal. Moreover, damaged brains reorganise so unless neuropsychological patients are tested immediately after the damage, it is difficult to assess the true effect of the lesion on behaviour. TMS, on the other hand, is so transitory, that the brain has no time to compensate for the 'lesion' and the true behavioural effects can be observed. Secondly, and perhaps most importantly, TMS can build on fMRI results, to demonstrate that activity within a cortical area is not simply correlated with, but necessary for a given task.

In conclusion, TMS produced a specific picture naming deficit. The absence of any effect on word/nonword reading or colour naming, suggests that left hemispheric posterior BA37 is necessary for object recognition. An important next step will be to investigate whether specific effects on phonological retrieval or semantic processing can also be attained with stimulation over more anterior sites.

Acknowledgements

This work was supported by the Medical Research Council. We are grateful to Vincent Walsh and Cathy Price for their helpful suggestions on earlier drafts of this paper and to James Rowe for his help with the structural MRI.

References

- [1] Albert ML. The anatomic basis of visual agnosia. *Neurology* 1997;6:876–9.

- [2] Amassian VE, Cracco RQ, Maccabee PJ, Cracco JB. Suppression of visual perception by magnetic coil stimulation of human occipital cortex. *Electroencephalography and Clinical Neurophysiology* 1989;74:458–62.
- [3] Brasil-Neto JP, McShane LM, Fuhr P, Hallett M, Cohen LG. Topographic mapping of the human motor cortex with magnetic stimulation: factors affecting accuracy and reproducibility. *Journal of Electroencephalography and Clinical Neurophysiology* 1992;85:9–16.
- [4] Burnstine TH, Lesser RP, Hart J, Jr, Uematsu S, Zinreich SJ, Krauss GL, Fisher RS, Vining EP, Gordon B. Characterization of the basal temporal language area in patients with left temporal lobe epilepsy. *Neurology* 1990;40:966–70.
- [5] Cambier J, Signoret JL, Bolgert F. Visual object agnosia: current conceptions. *Review Neurologique (Paris)* 1989;145:640–5.
- [6] Clark VP, Keil K, Maisog JM, Courtney S, Ungerleider LG, Haxby JV. Functional magnetic resonance imaging of human visual cortex during face matching: a comparison with positron emission tomography. *Neuroimage* 1996;1:1–15.
- [7] Démonet JF, Chollet F, Ramsay S, Cardebat D, Nespoulous JL, Wise R, Rascol A, Frackowiak R. The anatomy of phonological and semantic processing in normal subjects. *Brain* 1992;115:1753–68.
- [8] Démonet JF, Price CJ, Wise R, Frackowiak RSJ. Differential activation of right and left posterior sylvian regions by semantic and phonological tasks: a positron emission tomography study. *Neuroscience Letters* 1994;182:25–8.
- [9] D'Esposito M, Detre JA, Aguirre GK, Stallcup M, Alsop DC, Tippet LJ, Farah MJ. A functional MRI study of mental image generation. *Neuropsychologia* 1997;35:25–30.
- [10] George N, Dolan RJ, Fink GR, Baylis GC, Russell C, Driver J. Contrast polarity and face recognition in the human fusiform gyrus. *Nature Neuroscience* 1999;6:574–80.
- [11] Feinberg TE, Schindler RJ, Ochoa E, Kwan PC, Farah MJ. Associative visual agnosia and alexia without prosopagnosia. *Cortex* 1994;3:395–411.
- [12] Ferro JM, Santos ME. Associative visual agnosia: a case study. *Cortex* 1984;1:121–34.
- [13] Frith CD. In: Frackowiak RSJ, Friston KJ, Frith CD, Dolan RJ, Mazziotta JC, editors. *Human brain function*. New York: Academic Press, 1997:20–1.
- [14] Haxby JV, Horwitz B, Ungerleider LG, Maisog JM, Pietrini P, Grady CL. The functional organization of human extrastriate cortex: a PET-rCBF study of selective attention to faces and locations. *Journal of Neuroscience* 1994;11:6336–53.
- [15] Luders H, Lesser RP, Hahn J, Dinner DS, Morris H, Resor S, Harrison M. Basal temporal language area demonstrated by electrical stimulation. *Neurology* 1986;36:505–10.
- [16] Luders H, Lesser RP, Hahn J, Dinner DS, Morris HH, Wyllie E, Godoy J. Basal temporal language area. *Brain* 1991;114:743–54.
- [17] Kanwisher N, McDermott J, Chun MM. The fusiform face area: a module in human extrastriate cortex specialized for face perception. *Journal of Neuroscience* 1997;11:4302–11.
- [18] Kiyosawa M, Inoue C, Kawasaki T, Tokoro T, Ishii K, Ohyama M, Senda M, Soma Y. Functional neuroanatomy of visual object naming: a PET study. *Graefes Archives of Clinical and Experimental Ophthalmology* 1996;234:110–5.
- [19] Martin A, Haxby JV, Lalonde FM, Wiggs CL, Ungerleider LG. Discrete cortical regions associated with knowledge of color and knowledge of action. *Science* 1995;270:102–5.
- [20] Moore CJ, Price CJ, Friston KJ, Frackowiak RSJ. Phonological retrieval and semantic processing during naming tasks. 2nd International Conference on Functional Imaging of the Human Brain 1996; Abstract S449.
- [21] Moore CJ, Price CJ. Three distinct ventral occipitotemporal regions for reading and object naming. *Neuroimage* 1999;10:181–92.
- [22] Moscovitch C, Kapur S, Köhler S, Houle S. Distinct neural correlates of visual long-term memory for spatial location and object identity: a positron emission tomography study in humans. *Proceedings of the National Academy of Sciences USA* 1995;92:3721–5.
- [23] Plaut DC, McClelland JL, Seidenberg MS, Patterson K. Understanding normal and impaired word reading: computational principles in quasi-regular domains. *Psychological Review* 1996;103:56–115.
- [24] Price CJ, Moore CJ, Humphreys GW, Frackowiak RS, Friston KJ. The neural regions sustaining object recognition and naming. *Proceedings of the Royal Society London Series B* 1996;263:1501–7.
- [25] Price CJ, Friston KJ. Cognitive conjunction: a new approach to brain activation experiments. *Neuroimage* 1997;5:261–70.
- [26] Puce A, Allison T, Asgari M, Gore JC, McCarthy G. Differential sensitivity of human visual cortex to faces, letterstrings, and textures: a functional magnetic resonance imaging study. *Journal of Neuroscience* 1996;16:5205–15.
- [27] Rosier A, Cornette L, Dupont P, Bormans G, Michiels J, Mortelmans L, Orban GA. Positron-emission tomography imaging of long-term shape recognition challenges. *Proceedings of the National Academy of Sciences USA* 1997;94:7627–32.
- [28] Sergent J, Ohta S, MacDonald B. Functional neuroanatomy of face and object processing. A positron emission tomography study. *Brain* 1992;115:15–36.
- [29] Snodgrass JG, Vanderwaart M. A standardized set of 260 pictures: norms for name agreement, image agreement, familiarity, and visual complexity. *Journal of Experimental Psychology (Human Learning and Memory)* 1980;6:174–215.
- [30] Stewart L, Walsh V, Rothwell JC. Motor and phosphene thresholds: a TMS correlation study. *Neuropsychologia*, in press.
- [31] Talairach J, Tournoux P. *Co-planar stereotaxis atlas of the human brain*. Stuttgart: Georg Thieme, 1988.
- [32] Terao Y, Ugawa Y, Suzuki M, Sakai K, Hanajima R, Gemba-Shimizu K, Kanazawa I. Shortening of simple reaction time by peripheral electrical and submotor-threshold magnetic cortical stimulation. *Experimental Brain Research* 1997;115:541–5.
- [33] Ueno S, Tashiro T, Harada K. Localized stimulation of neural tissues in the brain by means of a paired configuration of time-varying magnetic fields. *Journal of Applied Physics* 1988;64:5862–4.
- [34] Vandenberghe R, Price C, Wise R, Josephs O, Frackowiak RS. Functional anatomy of a common semantic system for words and pictures. *Nature* 1996;383:254–6.
- [35] Walsh V, Cowey A. Magnetic stimulation studies of visual cognition. *Trends in Cognitive Sciences* 1998;2:103–8.
- [36] Warburton E, Wise RJ, Price CJ, Weiller C, Hadar U, Ramsay S, Frackowiak RS. Noun and verb retrieval by normal subjects. Studies with PET. *Brain* 1996;119:159–79.
- [37] Zelkowitz BJ, Herbster AN, Nebes RD, Mintun MA, Becker JT. An examination of regional cerebral blood flow during object naming tasks. *Journal of the International Neuropsychological Society* 1998;4:160–6.